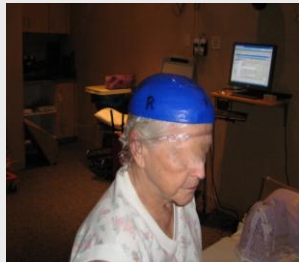

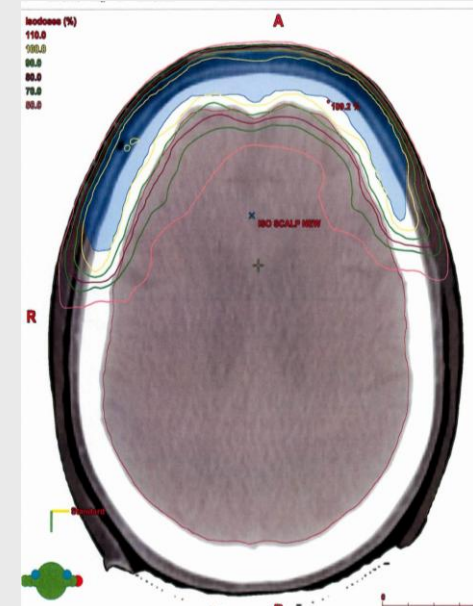
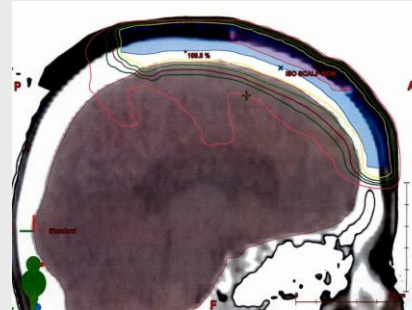


PATIENT HISTORY

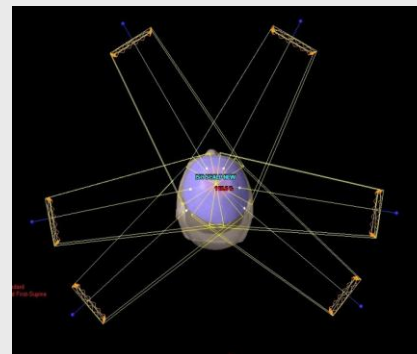
- 80 year old female
- Believed to be a sebaceous cyst
- May of 2012 Pathological findings determined malignant fibrous histiocytoma (MFH) of the scalp



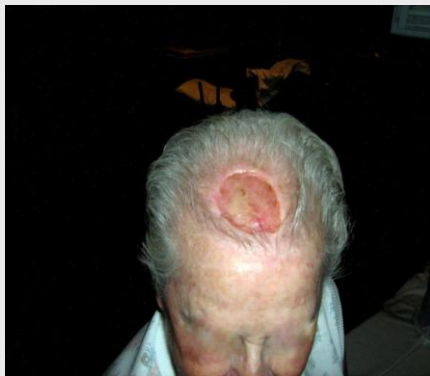DOSE PLANNING



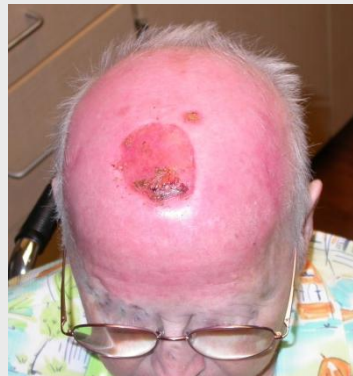PRESCRIPTION AND TREATMENT PLAN



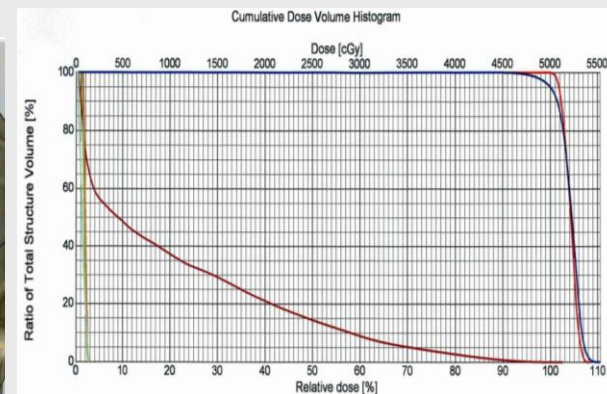
- Initial Plan: 6 Field IMRT to reduce dose to brain and critical cranial structures
- 5000 cGy / 25 fractions
- IMRT boost: 1000 cGy / 5 fractions
- Nanodots verified dose was accurate (0.3-3.9%)



Before Treatment

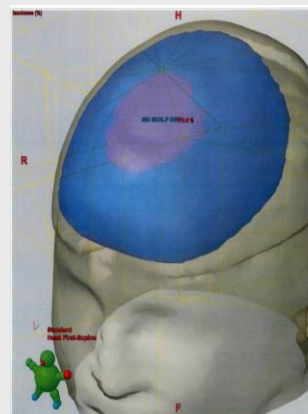


Last Day of Treatment



SUMMARY

- Customized bolus device delivered highly dose distribution.
- Dose distribution for skin dose very accurate and increased for customized bolus treatment technique.



Structure	Structure Status	Coverage (%/%)	Volume	Min Dose	Max Dose	Mean Dose	Modal Dose	Median Dose	Std Dev
Rt eye	Approved	100.0 / 100.0	6.1 cm ³	1.3%	2.8%	2.2%	1.9%	2.0%	0.3%
Lt eye	Approved	100.0 / 100.1	7.2 cm ³	1.2%	2.8%	1.9%	1.7%	1.8%	0.3%
CTV tumor bed	Approved	100.0 / 100.0	12.3 cm ³	99.6%	108.3%	104.2%	105.0%	104.3%	1.4%
Brainstem	Approved	100.0 / 100.0	26.0 cm ³	0.4%	23.9%	1.4%	0.5%	1.5%	6.6%
PTV 5000	Approved	100.0 / 99.9	235.4 cm ³	85.0%	110.8%	104.2%	105.3%	104.5%	2.3%
brain	Approved	100.0 / 100.0	1292.3 cm ³	0.5%	102.5%	20.5%	0.6%	9.0%	23.7%